

# An Atypical Presentation of Kikuchi-Fujimoto Disease: A Case Report & Literature Review

Abdul Rahman Halawa<sup>1</sup>, Muayad Ahmad<sup>1</sup>, and Abdulqadir Nashwan<sup>1</sup>

<sup>1</sup>Hamad Medical Corporation

June 10, 2020

## Abstract

Kikuchi-Fujimoto Disease (KFD) is a self-limiting condition that typically presents with lymphadenopathy and fever. It's autoimmune in nature, and possibly associated with systemic lupus erythematosus (SLE). The case report highlights an unusual case of KFD associated with autoimmune hemolytic anemia and provided a review for other atypical presentations.

## Hosted file

KFD\_Manuscript\_v0-1.docx available at <https://authorea.com/users/331887/articles/458378-an-atypical-presentation-of-kikuchi-fujimoto-disease-a-case-report-literature-review>

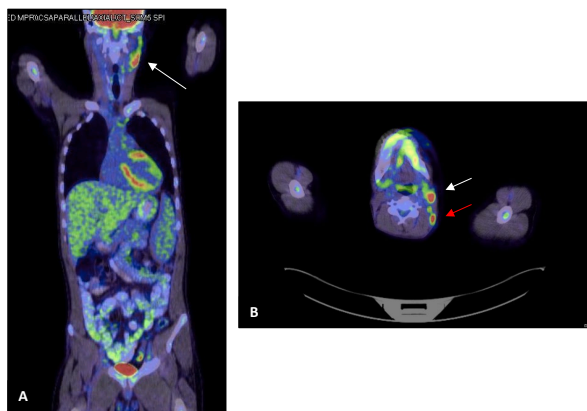


Figure 1A. Hypermetabolic left cervical lymph node, 1.3cm in diameter, SUV of 12.2. (White arrow)

Figure 1B. Left posterior neck is also showing few nodes around 7-9 mm with SUV extending up to 7.7. (Red Arrow)

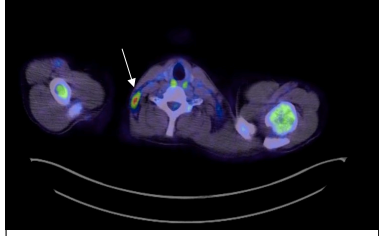


Figure 2. Hypermetabolic right cervical lymph node, 0.9 cm in size, SUV of 8.5. (White arrow)

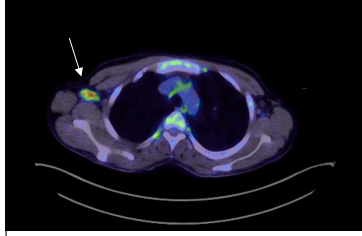


Figure 3. Hypermetabolic right axillary lymph node, 1cm size, SUV up to 6.9. (White arrow)